


Magnetic Black-Star®

Aim of the Study

The primary goal was to demonstrate the success of stent removal without the need for additional general anesthesia (GA) with a Magnetic Black-Star (MBS) stent. Secondly, the success of stent insertion and associated morbidity were evaluated.



Study Layout

In this monocentric, retrospective feasibility study 100 children (65 boys, mean age 7.8 years) were treated with a MBS between Nov. 2016 and Dec. 2019. Stent selection was based on surgeon preference. Exclusion: children < 1 year with pyeloplasty or retrograde cystoscopy.

Successful use of MBS

84% success with insertion

98% success with removal

81% success over all
(insertion + removal)

Challenges of Stenting in the Treatment of Children

Besides the fact that DJ removal is generally time consuming and costly (resources, operation room, staff), in children we need to consider the effects of

- (repeated) surgical experience
- potential neurotoxicity of repeated GA exposure^[2]

Easy Stent Removal in Outpatient Setting

Stent removal took place **without GA** in an **outpatient setting** using the special retrieval device – similar to an urethral catheter with magnetic tip – with a 2% lidocaine jelly lubricant and nitrous oxide/oxygen for pain and anxiety reduction. No special learning curve was experienced, even in boys and toddlers the removal device was easily introduced into the urethra. The children went home right after the retrieval.

Insertion

- Insertion of the MBS was successful in all cystoscopy (retrograde) placements (n=10) and all open surgeries (kidney transplant n=23 and ureteral reimplantation n=20).
- Antegrade insertion with laparoscopic pyeloplasty (n=47) was challenging with failures in 33% of these cases (stuck at UreteroVesical Junction (UVJ) n=14, visible at vulva n=2).
- Similar challenges are encountered with regular stents as well.
- The success rate drastically improved with increasing experience.

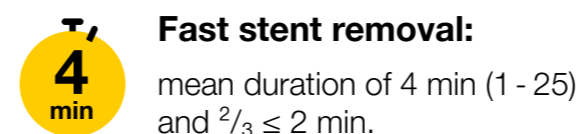
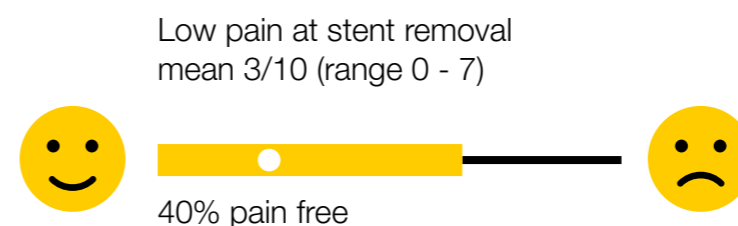
„...stent insertion was the only difficulty we encountered ... owing to the tiny UVJ in children. ... We believe that the passage of the UVJ will become easier with experience, especially because smaller magnetic beads are being developed.“^[1]

Retrieval

All but 2 stents could be easily removed with the retrieval device.

Both failures occurred as the magnet was hidden in a bladder diverticulum with impossible magnetic connection and were extracted like regular stents via cystoscopy (2 boys with kidney transplants).

Pain and stent removal time were assessed for the last 55 patients:



Advantageous in children

Feasibility and safety of magnetic-end double-J ureteral stent insertion and removal in children. World J Urol (2020).

Dr. Thomas BLANC
Necker-Enfants Malades University
Children Hospital, Paris, France

Advantages of using Magnetic Black-Star

- easy and fast removal without GA
 - no second surgery experience, no fasting
 - child can go home immediately after stent retrieval
 - similar insertion to regular DJ
 - no learning curve for retrieval
 - no added morbidity
 - reduction of removal time, cost, operation-room and staff occupancy vs. regular DJ
- Disadvantage: MRI contraindicated

Conclusion

„The analysis [...] in a large cohort of children demonstrates that this strategy is safe, with a low failure rate obviating the need for additional GA.“^[1]

Reference:
[1] Chalhoub M, et al. World J Urol (2020). DOI: 10.1007/s00345-020-03339-0 [2] McCann ME, et al. BMJ 367:16459; DOI: 10.1136/bmj.16459